

Basic Ophthalmology Note Template

Date:

ID: 77 y/o female known for _____

RFR: Referred for ___/Follow-up___

HPI: Decreased vision? Pain? Tearing? Redness?
Flashes/Floaters? Black curtain loss of vision? Worse when reading or in the distance? Double vision? Pain with EOMs? Photophobia?

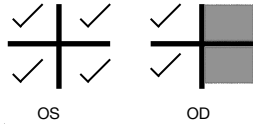
O/E:

V ^{OD} cc 20/20
_{OS} sc 20/200

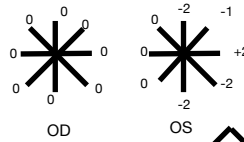
P ^{PERRL, No RAPD}
_{PERRL, No RAPD}

T ¹¹
_{Tono/TA 14}

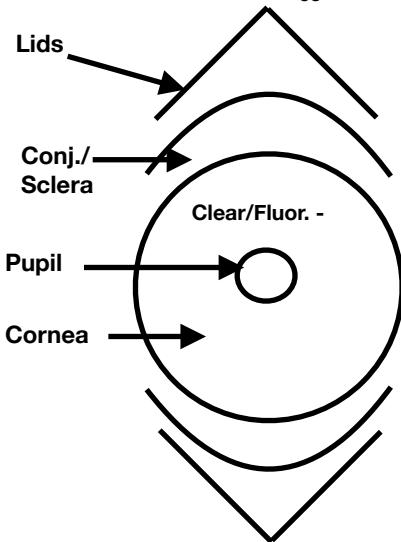
VF



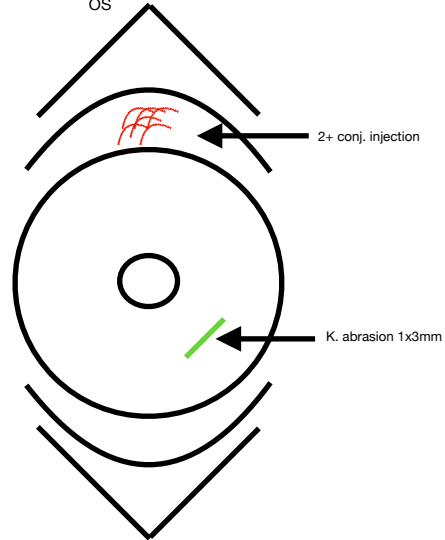
EOM [-3,3]



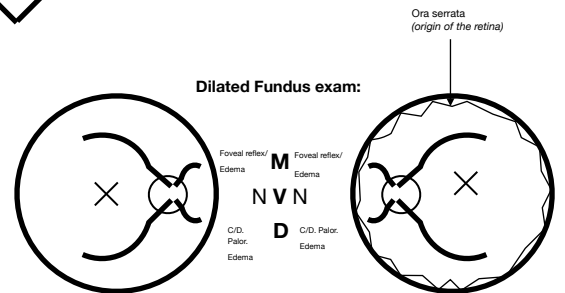
SLE:



Normal	LLL	Normal
Clear	SC	Clear
Clear, no injection	Conj	Clear, no injection
Clear/Fluor. -	K	Clear/Fluor. -
Deep& quiet (no cells)	A/C	Deep& quiet (no cells)
Normal, No NVI, pupil round	I	Normal, No NVI, pupil round
NSC vs PCIOL in place	L	NSC vs PCIOL in place



Dilated Fundus exam:



Legend :
 CC: with correction SC: without correction
 PERRL : pupil equal and reactive to light
 ap : applanation
 VF: visual fields
 EOM : extra-ocular movements
 LLL: external - eyelids/lashes
 SC: sclera
 C: conjunctiva
 K: cornea
 A/C : anterior chamber
 I : iris
 L: Lens
 N : Nerve
 M: macula
 C/D : cup to disc ratio
 V: Vessels
 NVI : iris neovascularization
 PCIOL: posterior capsule intra-ocular lens
 NCS:nuclear sclerosis cataract

Imp:
1.

Plan :
1.